


# Moria



## SBK without compromise using Moria One Use-Plus



One Use-Plus **SBK**



### One Use-Plus by numbers



**+2 million patients operated**



**+120,000 eyes followed**  
in peer-reviewed protocols



**+300,000 patients treated /**  
year since last 3 years



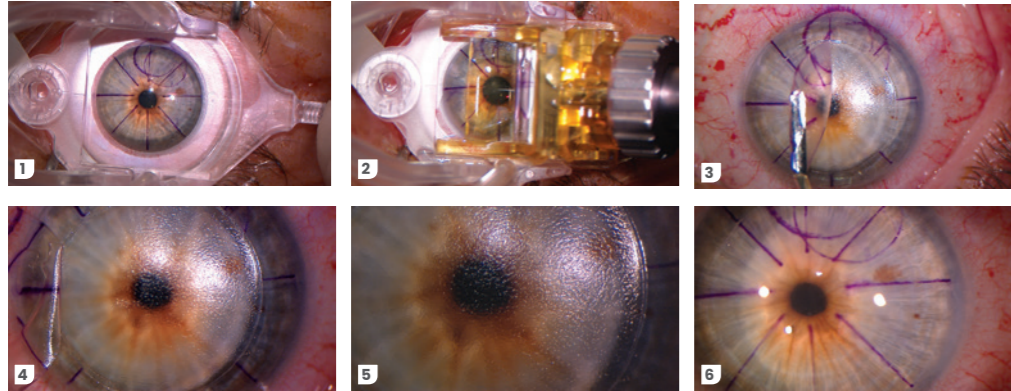
**+45 peer-reviewed**  
published studies

## SBK WITHOUT COMPROMISE TO REACH ...



### Flap creation in less than 4 seconds for a minimal suction time, potentially preserving goblet cells<sup>1</sup>

- ▶ with a full intraoperative visibility during the whole flap creation

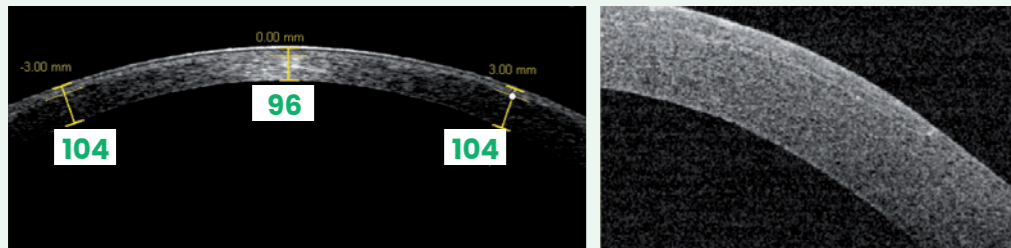


Sequence showing flap creation and lifting on a patient's right eye using Moria One Use-Plus SBK. Courtesy of James S. Lewis, MD (Elkins Park, PA, USA)



### Predictible thin sub-Bowman flaps centrally<sup>2-12</sup>

- ▶ with a high reproducibility between OD then OS<sup>2-4,8,12</sup>
- ▶ with a planar profile/architecture throughout the whole flap surface<sup>5-7</sup>



Anterior segment OCT pictures of a nasal-hinged corneal flap profile created using Moria One Use-Plus SBK. Courtesy of James S. Lewis, MD (Elkins Park, PA, USA)


When using the SBK 90- $\mu$ m calibrated head, mean central flap thickness is:

- ▶ at **Speed 2 (fast motion): 100  $\pm$  10 [80 – 120] microns**
- ▶ at Speed 1 (slow motion): 110  $\pm$  10 [90 – 130] microns




### Excellent stromal surface smoothness for an accurate photoablation

- ▶ confirmed by Scanning Electron Microscopy<sup>13</sup>
- ▶ no « velcro-type » surface for a crystal clear anatomical flap apposition<sup>6,13-14</sup>



X20



X160

Scanning Electron Microscopy pictures at different magnifications after cutting a flap with Moria One Use-Plus SBK with an intended flap thickness of 100 microns. Courtesy of Richard J. Duffey, MD (Mobile, AL, USA)<sup>13</sup>

## ... HIGHLY-EXPECTED PATIENT SATISFACTION



### Excellent safety profile

#### ▶ intraoperatively

- no buttonhole, no incomplete flap, no epithelial erosion, no irregular stromal bed reported in a large-scale retrospective study on flat corneas (2883 eyes)<sup>14</sup>
- with very large flaps (>9.5 mm) required for high hyperopia and presbyopia corrections<sup>15</sup>

#### ▶ postoperatively

- no single flap displacement<sup>14</sup>, no haze nor energy-related DLK<sup>16</sup>
- one of the lowest incidence rate of epithelial ingrowth (0.49%) in a large-scale cohort study<sup>17</sup>
- one of the lowest myopic & hyperopic LASIK retreatment rates in large-scale cohort studies: <0.5% & 4.6% respectively<sup>18-19</sup>




### In terms of in-vivo confocal microscopy research comparing SBK to Femto-LASIK and other microkeratome<sup>6</sup>

- ▶ higher density of stromal keratocytes at 3 months postoperatively
- ▶ faster regenerative velocity of subbasal nerve fibers due to the nasal hinge which preserves more anatomically-placed corneal nerve branches.



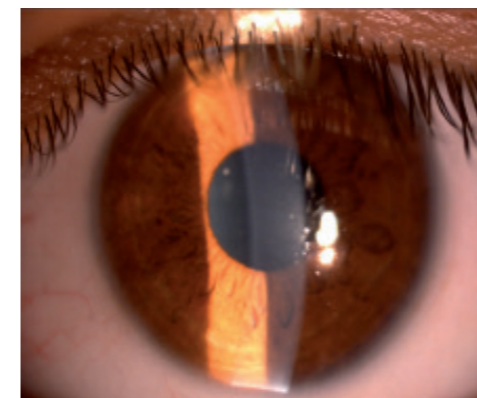
### Very fast visual recovery

- ▶ equivalent to Femto-LASIK<sup>11</sup>
- ▶ providing a real « WoW » effect far awaited by every patient



### Excellent quality of vision


- ▶ limited changes of higher order aberrations (HOAs)<sup>9,20-22</sup>
- ▶ and evenly less induction of total HOAs and spherical aberrations than during Femto-LASIK<sup>23</sup>
- ▶ intraocular straylight measurements equivalent to Femto-LASIK<sup>24</sup>
- ▶ negligible changes of higher order Point Spread Function (PSF) Strehl ratio, preserving an optimal retinal image quality<sup>21</sup>



Slit-lamp picture of a SBK flap at Day 1 postoperative: edges are almost invisible. Courtesy of Ahmed El-Massry (Alexandria, Egypt)

## WHAT MAKES ONE USE-PLUS MICROKERATOME

the state-of-the-art in today's automated microkeratomes



### Excellent ergonomics for a user-friendly automated microkeratome



- ✓ **Automated linear motion** to benefit from **nasal hinge**<sup>3,7,10,12,17,19</sup>
- ✓ Pre-assembled and one-handed usage possible
- ✓ Safety and reliability of two independent motors: one for head advancement, one for blade oscillation



- ✓ **Wide range of suction rings** to individualize flap geometry based on photoablative patterns: from oval-shaped to extra-large hyperopic treatments<sup>15</sup>
- ✓ **Adjustable stops** for customized hinge length
- ✓ Design of suction ring makes the use of a speculum unnecessary on small fissures
- ✓ Translucent single-use plastic ring enables visual confirmation of suction



- ✓ **Unique choice of single-use calibrated cutting heads & suction rings & aspiration tubings**
- Single-use means simplicity, safety, convenience, and ease-of-use:

- ✓ Protected blade to avoid potential damage
- ✓ Limits complications and risks linked to damaged or improperly maintained reusable heads
- ✓ Unique solution to limit infection and contamination from prions, virus, bacteria, germs and other micro-organisms<sup>25-27</sup>



#### And as a bonus:

- ✓ Single-use heads and rings facilitate compliance with ASCRS guidelines which recommend not using flash sterilization
- ✓ Eliminates sterilization and maintenance
- ✓ Lower initial investment costs
- ✓ More rapid patient turnover, leading to greater efficiency



#### The most economical platform for SBK:

- ✓ Limited capital investment and cost per surgery
- ✓ Make your own comparisons between the One Use-Plus and a femtosecond laser in terms of capital investment, disposables per patient, and annual maintenance.


# PRODUCT REFERENCES

One Use-Plus handpiece




19345

One Use-Plus – heads 90/130



19393/90  
19393/130


One Use-Plus: metallic reusable suction rings




19391/-1  
19391/0



19391/1  
19391/2  
19391/3




19519/-1




19391/1/OV  
19391/2/OV  
19391/3/OV

One Use-Plus: single-use plastic suction ring & head



XX = 90 - 130  
XXX = 110 - 130



19336/XX  
19337/XX  
19354/XXX

	#19345	#22519514	#22519513	#19391/0	#19391/1	#19391/2	#19391/3
SETM	✓	✓	✓	-	-	-	-
SETM9	✓	✓	✓	✓	✓	✓	✓

## SETM: ONE USE-PLUS Set

Set containing the One Use-Plus microkeratome for LASIK surgery:

- One Use-Plus handpiece: **#19345**
- storage box for One Use-Plus microkeratome: **#22519514**
- sterilization box for One Use-Plus suction rings: **#22519513**

## SETM9: ONE USE-PLUS Set (Metal Rings)

Set containing the One Use-Plus microkeratome for LASIK surgery with 4 reusable metallic suction rings:

- One Use-Plus handpiece: **#19345**
- storage box for One Use-Plus microkeratome: **#22519514**
- sterilization box for One Use-Plus suction rings: **#22519513**
- One Use-Plus reusable suction ring, size 0: **#19391/0**
- One Use-Plus reusable suction ring, size +1: **#19391/1**
- One Use-Plus reusable suction ring, size +2: **#19391/2**
- One Use-Plus reusable suction ring, size +3: **#19391/3**

## BIBLIOGRAPHY

- Xu et al.** Dry eye after Small Incision Lenticule Extraction and LASIK for myopia. *J Refract Surg.* **2014**;30(3):186-190.
- Chen et al.** Anterior segment optical coherence tomography measurement of flap thickness after myopic LASIK using the Moria One Use-Plus microkeratome. *J Refract Surg.* **2010**;26(6):403-410.
- Lian et al.** Correlation analysis and corneal flap thickness changes among Moria SBK, 90 and 110 microkeratome in LASIK. *Chin Ophthalmic Res.* **2010**;28(12):1158-1161.
- Du et al.** Flap thickness variation with 3 types of microkeratome heads. *J Cataract Refract Surg.* **2011**;37(1):144-148.
- Sun et al.** Comparisons of morphologic characteristics between thin-flap LASIK and SBK. *Int J Ophthalmol.* **2012**;5(2):338-342.
- Zhang et al.** Confocal comparison of corneal nerve regeneration and keratocyte reaction between FS-LASIK, OUP-SBK, and conventional LASIK. *Invest Ophthalmol Vis Sci.* **2012**;53:5536-5544.
- Zhai et al.** Comparison of the flaps made by femtosecond laser and automated keratomes for Sub-Bowman Keratomileusis. *Chin Med J.* **2013**;126(13):2440-2444.
- Zhang et al.** Comparison of corneal flap thickness using a FS200 femtosecond laser and a Moria SBK microkeratome. *Int J Ophthalmol.* **2014**;7(2):273-277.
- Al-Thomali TA.** Reproducibility of flap thickness in Sub-Bowman Keratomileusis using a mechanical microkeratome. *J Cataract Refract Surg.* **2014**;40(11):1828-1833.
- Mimouni et al.** Factors affecting laser in situ keratomileusis flap thickness: comparison of 2 microkeratome heads. *J Cataract Refract Surg.* **2015**; 41(2):348-353.
- Xu et al.** The impact of flap creation methods for Sub-Bowman's Keratomileusis (SBK) on the central thickness of Bowman's layer. *PLoS ONE* **2015**;10(5):e0124996.
- Katz et al.** Flap-induced astigmatism in eyes with sphere myopia correction: superior hinge using a rotating microkeratome versus nasal hinge using a linear microkeratome. *J Cataract Refract Surg.* **2015**;41(6):1160-1167.
- Duffey RJ.** Moria One Use-Plus SBK microkeratome: predictably thin, smooth, planar flaps for faster visual recovery. Paper presented during the 26<sup>th</sup> annual meeting of European Society of Cataract and Refractive Surgery; Sept 13-17, **2008**; Berlin, Germany.
- Falcon et al.** Safety of the automated microkeratome for Sub-Bowman's Keratomileusis on the flat cornea. *French J Ophthalmol.* **2016**;39(2):202-209.
- Gauthier-Fournet et al.** Six-month outcomes after high hyperopia correction using Laser-Assisted In Situ Keratomileusis with a large ablation zone. *Cornea* **2019**;38(9):1147-1153.
- Kasetsuwan et al.** Comparison of performances of femtosecond laser and microkeratome for thin-flap Laser In Situ Keratomileusis. *Lasers Surg Med.* **2016**;48(6):596-601.
- Friehmann et al.** Risk factors for epithelial ingrowth following microkeratome-assisted LASIK. *J Refract Surg.* **2018**;34(2):100-105.
- Pokroy et al.** Myopic laser in situ keratomileusis retreatment: incidence and associations. *J Cataract Refract Surg.* **2016**;42(10):1408-1414.
- Mimouni et al.** Risk factors for re-treatment following hyperopic LASIK. *J Refract Surg.* **2018**;34(5):316-320.
- Hassanin et al.** Changes in corneal wavefront aberrations and asphericity following optimized LASIK ablation in moderate to highly myopic eyes. *J Applied Sci Res.* **2013**;9(3):2404-2410.
- McAlinden et al.** Comparison of Higher Order Aberrations after LASIK and LASEK for myopia. *J Refract Surg.* **2010**;26(1):45-51.
- McAlinden et al.** The change in internal aberrations following myopic corneal laser refractive surgery. *Graefes Arch Clin Exp Ophthalmol.* **2011**;249(5):775-781.
- Malhotra et al.** Higher Order Aberrations and visual outcomes in Wavefront-Optimized Sub-Bowman Keratomileusis: flap creation using femtosecond laser versus mechanical microkeratome. *Asia Pac J Ophthalmol.* **2015**;4(4):197-203.
- Wang et al.** Intraocular straylight after thin-flap LASIK with a femtosecond laser versus a mechanical microkeratome. *J Refract Surg.* **2013**;29(8):534-539.
- Orrù et al.** Prion seeds distribute throughout the eyes of sporadic Creutzfeldt-Jakob disease patients. *mBio* **2018**;9:e02095-18.
- Chen et al.** Ocular manifestations of a hospitalised patient with confirmed 2019 novel coronavirus disease. *Br J Ophthalmol.* **2020**;104(6):748-751.
- Kumar et al.** Presence of viral RNA of SARS-CoV-2 in conjunctival swab specimens of COVID-19 patients. *Indian J Ophthalmol.* **2020**;68(6):1015-1017.

 **MORIA SA**  
27, rue du Pied de Fourche  
03160 Bourbon L'Archambault  
FRANCE  
Phone: +33 (0)1 46 74 46 74  
Fax: +33 (0)1 46 74 46 00  
[moria@moria-int.com](mailto:moria@moria-int.com)  
[www.moria-surgical.com](http://www.moria-surgical.com)

**MORIA Inc**  
1050 Cross Keys Drive  
Doylestown, PA 18902  
USA  
Phone: (800) 441 1314  
Fax: +1 (215) 230 7670  
[orders@moriausa.com](mailto:orders@moriausa.com)  
[www.moria-surgical.com](http://www.moria-surgical.com)

**Moria**

**Moria Japan K.K.**  
Arcadia Building 6F  
1-12-3 Kanda  
SudachoChiyoda-Ku  
Tokyo 101-0041  
JAPAN  
Phone: 81-3-6260-8309  
Fax: 81-3-6260-8310  
[moria@moriajapan.com](mailto:moria@moriajapan.com)  
[www.moriajapan.com](http://www.moriajapan.com)

**Moria COMMERCIAL (CHINA) CO., LTD.**  
上海自利亚贸易有限公司  
Room H 6F Kaili Building NO.432  
West Huai Hai Road, Changning district, Shanghai, 200052, P.R.C  
中国上海市长宁区淮海西路432号  
凯利大厦6楼08室  
Phone/Fax: +86 021 52586095  
[moriachina@moria-int.com](mailto:moriachina@moria-int.com)

