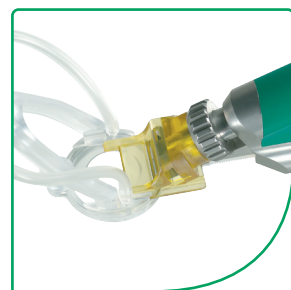

Epi-LASIK Surgery



Epi-K™

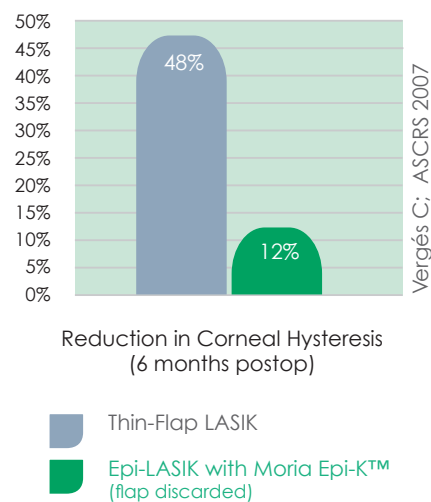
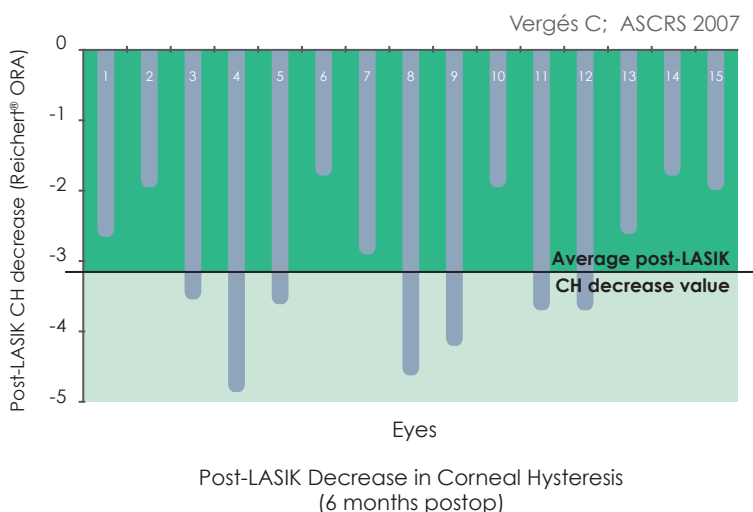
The procedure of choice
for surface ablation.



Moria
Leading Innovations in Ophthalmology

Preservation of Corneal Biomechanical Integrity, minimizing the risks of ectasia

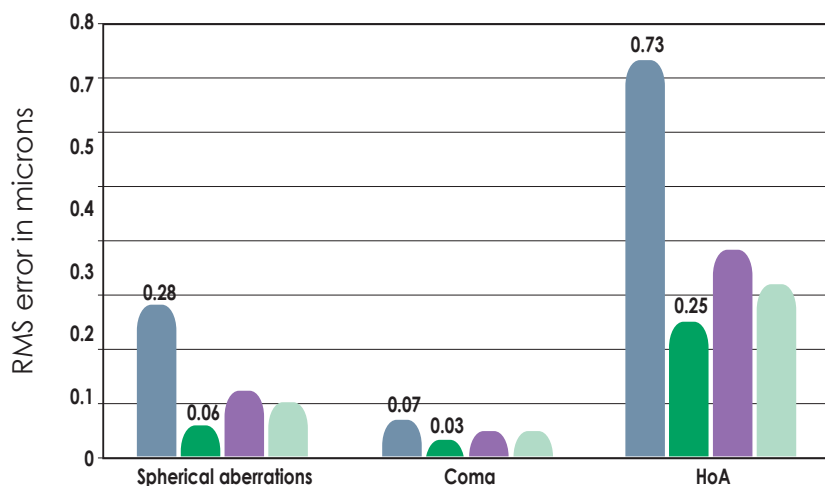
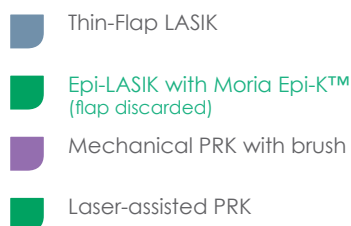
The Reichert® Ocular Response Analyzer device fires a rapid air pulse at the cornea and records separate applanation pressure measurements as the air puff hits the cornea and bounces back. The difference between the two pressure values is corneal hysteresis (CH). Low CH demonstrates that the cornea is less capable of absorbing or damping the energy of the air pulse.



Fewer Induced Higher Order Aberrations

Changes in Higher order Aberrations (HoA) 6 months follow-up

Vergés C; ASCRS 2007

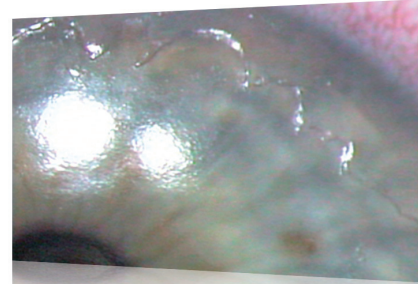

Faster Healing than All Other Surface Ablation Procedures

Alcohol-assisted PRK

- Use of alcohol on the cornea potentially inducing inflammation.
- Devitalized cells pushed to center of the cornea, releasing cytokines.
- Pseudodendrites typically visible for one week or more and retard healing.
- Painful procedure.
- Average healing time: 7 days.
- Some patients require 10 days or longer.

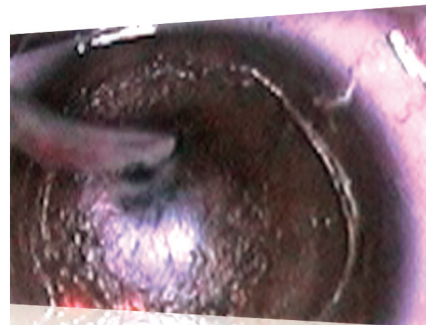
Epithelium and Bowman's membrane after alcohol removal¹



Mechanical PRK with a brush

- 80% of irregular edges with mechanical PRK with a brush.
- Average healing time: 5 days.
- Some patients require 7 days or longer.

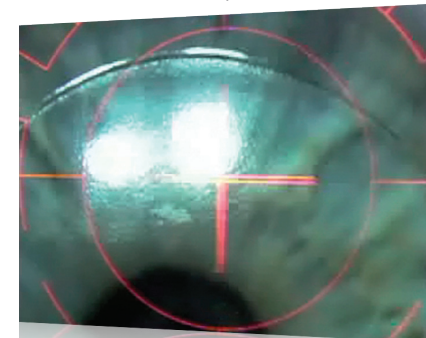
Epithelium and Bowman's membrane after mechanical PRK with a brush²



Epi-LASIK with Moria Epi-K™

- 100% of regular and clean-edges with Epi-LASIK using Moria Epi-K™².
- Very smooth surface.
- Epithelium adjacent to removed sheet is fully adherent and not traumatized by alcohol or brush debridement.
- Cornea thus re-epithelializes quickly.
- Several suction ring sizes to customize epithelial flap dimensions
- Average healing time: **42 hours to 3½ days**³
- Bandage contact lens removed sooner for a better experience for patient

Epithelium and Bowman's membrane after use of Moria Epi-K™¹



¹ Milne HL. Refractive Surgery Returns to the Surface. *Cataract and Refractive Surgery Today*. 2006; 6 (10): 41-44.

² Vergés C. Presented at the annual meeting of ASCRS in San Diego, USA in April 2007.

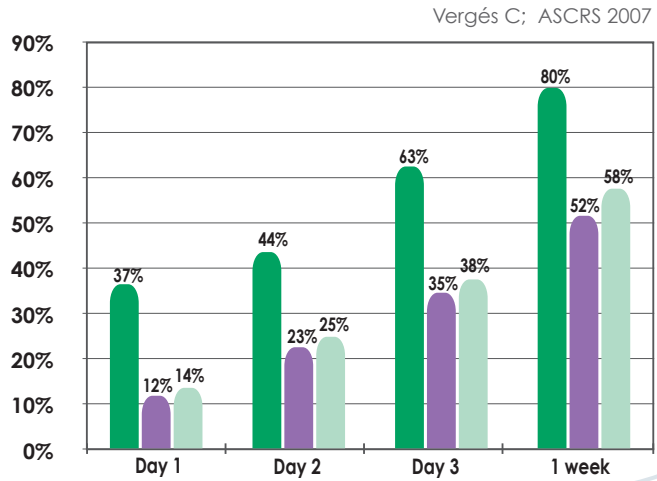
³ Michell R. Cornea epithelial healing rates after advanced surface treatment Epi-LASIK refractive surgery.

Paper presented during ASCRS 2010 (Boston, MA), ARVO 2010 (Fort Lauderdale, FL) and ESCRS Fall 2010 (Paris, France).

Faster Visual Recovery than All Other Surface Ablation Procedures

20/25 or Better Vision (UCVA)

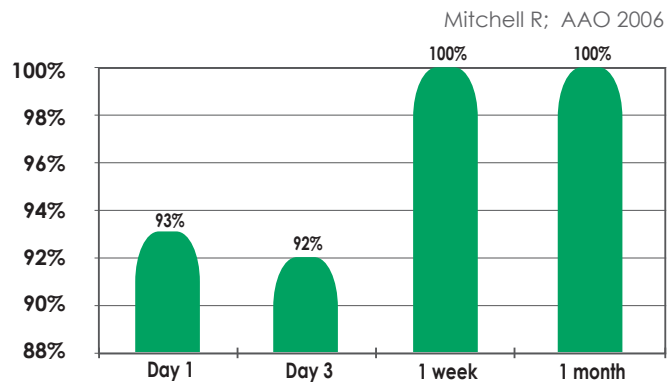
- Epi-LASIK with Moria Epi-K™ (flap discarded)
- Mechanical PRK with brush
- Laser-assisted PRK



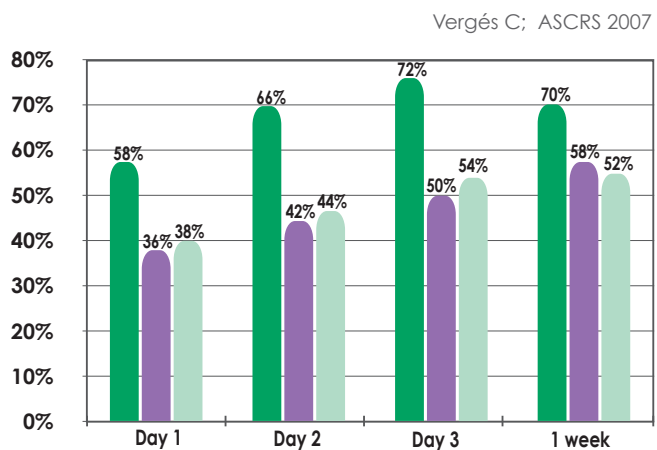
20/40 or Better Vision (UCVA)

Legal Driving Limit

- Epi-LASIK with Moria Epi-K™ (flap discarded)



- Epi-LASIK with Moria Epi-K™ (flap discarded)
- Mechanical PRK with brush
- Laser-assisted PRK



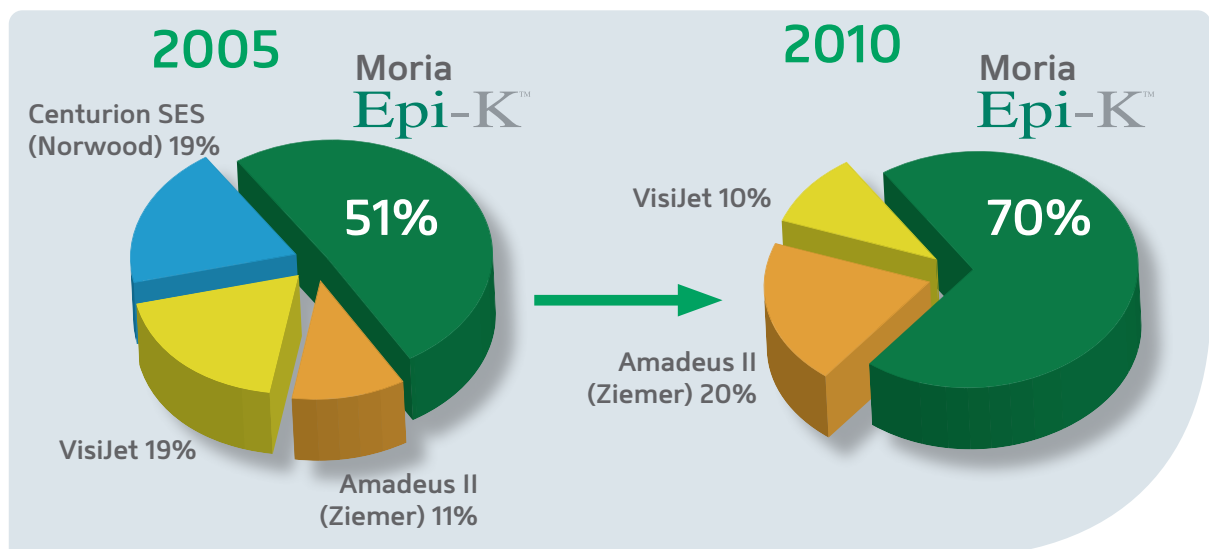
Epi-LASIK has changed greatly from its original form

- Most surgeons now discard the epithelial sheet.
- Moria Epi-K™ the most widely used epikeratome.
- New surgical techniques and pain management regimens.
- Appealing to safety-conscious patients.
- Distinguishing any refractive practice: gold standard for surface ablation.

and achieved impressive results

- More efficient in epithelial flap creation compared to other epikeratomes ⁴.
- Consistent epithelial separation.
- Preservation of corneal biomechanical integrity minimizing the risks of ectasia.
- Fewer induced higher order aberrations (HoA).
- Faster healing than all other surface ablation procedures.
- Faster visual recovery than all other surface ablation techniques.
- Very effective post-operative pain management.

The Moria Epi-K™ : The US Epikeratome Market Leader

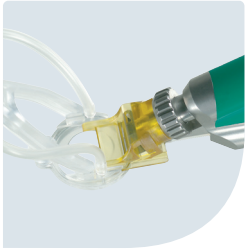

US Trends in Refractive Surgery Epikeratome used: 2005 ISRS and 2010 ISRS Survey by Duffey, Leaming, Wexler.


⁴ Choi SK, Kim JH, Lee D, Lee JB, Kim HM, Tchah HW, Hahn TW, Joo M, Ha CI. Different epithelial cleavage planes produced by various epikeratomes in epithelial laser in situ keratomileusis. *J Cataract Refract Surg.* 2008; 34: 2079–2084.

Epi-K™

powered by Moria



The optimal design for safe, reliable epithelial separation time after time.



- Metal separator with proprietary edge geometry specifically for cleaving rather than cutting.
- Disposable plastic head encases each separator for added safety and convenience.
- Appplanation plate provides yet an additional margin of safety.
- Single-Use suction ring option.
- Large diameter suction ring for hyperopes, flat corneas, wavefront-guided ablations, and lasers requiring large ablation zones.
- Small diameter suction rings more than adequate for the 6.0-mm optical zone treatments for myopes.
- Only 10- to 15-sec for the epithelial separation, short suction time
- Ideally paired with the One Use-Plus microkeratome, which shares the same technology platform.
- Evolution^{3E} console operates Epi-K™, all Moria microkeratomes, and the DSAEK system.

To obtain more information



MORIA SA
15, rue Georges Besse
92160 Antony
FRANCE
Phone: +33 (0) 1 46 74 46 74
Fax: +33 (0) 1 46 74 46 70
www.moria-surgical.com

MORIA Inc
1050 Cross Keys Drive
Doylestown, PA 18902
USA
Phone: (800) 441 1314
Fax: + 1 (215) 230 7670
www.moria-surgical.com

MORIA JAPAN KK
Inami Bldg. 6F
3-24-2 Hongo Bunkyo-ku
Tokyo 113-0033
JAPAN
Phone: + 81 3 5842 6761
Fax: + 81 3 5842 6762
www.moriajapan.com

MORIA in CHINA
Moria Commercial (China) Co. Ltd
Rm H, I, 6FL, Kai Li Building
N° 432 Huai Hai West Road
Shanghai 200052
CHINA
Phone: + 86 21 5258 5066
Fax: + 86 21 5258 5067
www.moria-surgical.com.cn

Moria
Leading Innovations in Ophthalmology