AcuPulse™ with Combo Treatment Modality: Clinical Study of Patients with Skin of Color

Michael H. Gold, MD
Gold Skin Care Center and Tennessee Clinical Research Center Inc., TN, USA

Introduction

Fractional laser therapy has become one of the mainstays of laser therapy around the world to treat a myriad of skin care concerns. Clinical evidence-based medicine has shown great success for these devices in improving the signs of photodamage, including fine lines and wrinkles, pigmentary dyschromias, and even skin laxity [1]. In addition, fractional lasers have shown to improve scars, whether acne scars or traumatic scars [2].

Many looking into the fractional world of lasers realize that in order to individualize the therapy to the specific patient and to the specific entity to be treated, we need to, at times, be able to generate laser "damage" that occasionally is superficial in nature and at times deep in its effects. This challenge has prompted the development of the AcuPulse Carbon Dioxide (CO_2) Laser System Combo treatment modality. In this report, we will review the system, early clinical experience, and new experience in utilizing this modality in skin of color, that make up more and more of our patient population on a day to day basis.

The concept of fractional lasers is fairly straightforward; create small columnar "holes" on fractional components of the skin and utilize the normal surrounding skin to help "heal" the fractional columns.

Non-ablative laser systems were the first fractional lasers introduced into the market approximately eight years ago. They truly helped treat photodamage and scars. However, non-ablative lasers require a series of treatments, usually 4-6 treatments, which are spread over a 4-6 month period of time. Heralded as no downtime procedures, most of the non-ablative devices do cause significant erythema and many will note erythema and edema that last post-therapy upwards of 48-96 hours [3].

History of AcuPulse Development

As our sophistication with fractional therapy increased, and our patients desired to see clinical improvement faster, the ablative fractional lasers came into being. Lumenis was the first to introduce fractional CO_2 laser resurfacing with the development of the ActiveFX™, followed by the DeepFX™application [4]. The Lumenis UltraPulse® Encore® CO_2 laser platform is considered one of the most sophisticated delivery systems ever created and one of the most popular CO_2 laser devices ever developed.

The ActiveFX application uses a spot size of 1.3 mm and a superficial or microablative fractional laser energy distribution. It uses a computer pattern generator (CPG) scanner to apply the injury pattern randomly across the scanning area, as opposed to being placed one next to another, as is the case in traditional laser resurfacing. This helps assure that the thermal relaxation time of tissue, which can be associated with increased risks from the procedure, is not compromised. In addition, the CPG utilizes the high energy of the UltraPulse laser that enables application of a spot size and pattern geometries that are insensitive to precise focal plane, allowing for a fast, more freehand delivery modality. The FDA clearance for the ActiveFX includes treatment of wrinkles, rhytids, furrows (fine lines and texture irregularities), reduction or removal of uneven pigmentation or dyschromias, and the treatment of acne scars.

Following the ActiveFX, a second computer-generated scanner was developed for the UltaPulse Encore. This second scanner produces a 0.12 mm diameter spot size that again delivers laser energy in a fractional manner, this time deeper into the dermis. This technology is known as the DeepFX and is designed to treat deeper lines and rhytids of the face as well as acne and traumatic scars.

When optimal and individualized therapy is indicated, many clinicians have combined both the ActiveFX and the DeepFX into a treatment that is now known as TotalFX™. This combination allows one to treat at various depths and targets that were difficult to improve prior to this therapy.

To simplify the mechanics of utilizing both a superficial and deep therapy with one device and with same scanner, Lumenis recently introduced the AcuPulse Combo treatment modality that enables a superficial and deep ablative treatment with a single scanner. Just as is in the UltraPulse fractional laser system, a deep component is possible utilizing the systems SuperPulse mode and a 0.12mm spot just as the DeepFX. For superficial modalities, the system takes this same 0.12mm spot with the same scanner and spreads the laser energy via a spiral delivery pattern over a larger spot of 1.3 mm resulting in a lower fluence and more superficial laser ablation.

Both the AcuPulse deep and superficial modes allow for fractional ablation to occur without compromising the thermal relaxation time of tissue, whic n would be associated with an increase in thermal damage and potential adverse events, including post-inflammatory hyperpigmentation (PIH), commonly seen in our darker-skinned skin of color patients. This spiral delivery of laser energy and distribution is shown in *Figure 1*. It is this new delivery of the superficial energy, and the ability to perform deep as well as superficial fractional ablation modes

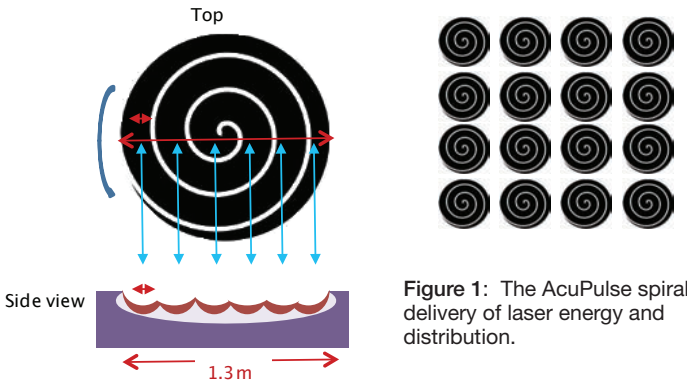

Figure 1: The AcuPulse spiral delivery of laser energy and distribution.

Figure 2: The AcuPulse system (Lumenis, Santa Clara, California).

in one hand piece, that differentiates this fractional carbon dioxide laser system from other fractional laser systems currently available. The system has a very easy user interface with touch-screen control to allow the user to easily maneuver from deep to superficial and back again, based on the parameters needed, as shown in *Figure 2*.

Clinical Study

In a recent study [5], Gold and Biron looked at 15 individuals with photo-damaged skin, with emphasis on the improvements achieved in fine lines and wrinkles as well as the overall skin texture in the treated individuals. These patients received a Combo treatment; deep AcuPulse treatment in the perioral and periorbital regions followed by a full-face superficial treatment modality. The AcuPulse treatment parameters used in this initial clinical trial were as follows: for the deep fractional component, energy was 5-20 mJ in a superpulse mode, and a density of 5-15%; for the superficial component, 50-170 mJ were used at a density of 40-60%. Each patient was treated once and then returned for follow-up visits at 7 days, 30 days, and 90 days following the therapy.

Effectiveness as assessed by improvement of wrinkles, pigmentation, and overall skin improvement was good-very good as rated by the investigator in 50% of the subjects. The average wrinkle score and pigment score mirrored this effectiveness with reduction from 4.3 and 4 to 2.8 and 2.7, respectively, at the end of the study. This reduction was statistically significant as compared to baseline ($p<0.01$, t-test for paired data). Subject assessment and satisfaction confirmed the results as at least 65% of the subjects graded the results as good-very good at the three month follow-up visit and more than 85% of the subjects were satisfied with the treatment. There was a high correlation (0.79) between the subject's perception of improvement and satisfaction. From this first initial clinical evaluation, the decision to treat skin of color was undertaken in five individuals to be described.

Treatment of Skin Of Color

Five, male and female patients, skin type IV-V, with various textural lesions (photodamage, severe wrinkling, acne scarring) were selected for this evaluation. Informed written consent was received from each of the patients. The treating physician evaluated each patient and pre and post -operative written instructions were given and reviewed with each patient.All patients were then scheduled for their single AcuPulse Combo treatment. Patients were instructed to avoid sun exposure for 2 weeks before and 4 weeks after the treatment and to apply broad-spectrum sunscreen (at least 30 SPF) daily during the study period.

At the time of treatment, the skin of the face was thoroughly cleansed in the office with a mild non-soap cleanser to assure that the skin was clean; make-up was removed on female patients. A topical anesthesia mixture (Benzocaine 20%, Lidocaine 6%, Tetracaine 5%) was applied to the entire facial skin for 60 minutes. Care was taken to thoroughly remove the anesthetic and an AcuPulse Combo treatment was performed. Patients were asked to evaluate the downtime after the treatment and to return one week, 1 and 3 months after the treatment for follow-up evaluation.

Results

Three female and two male patients, age 24-67, skin types IV (n=3) and V (n=2) completed the evaluation. *Figure 3* shows a 37-year-old Filipino, male patient with Fitzpatrick Skin Type IV and a long history of acne scars (*Figure 3A*). His immediate post-operative appearance is shown in *Figure 3B*. Post-laser therapy skin care utilized in this clinical evaluation was the same for all of the patient's studied and included the use of Cicalfate (Pierre Fabre, Toulouse, France) followed by the use of Avene Spray Water (Pierre Fabre, Toulouse, France). A gentle cleansing lotion was provided to the patients, either Avene or Neocutis (San Francisco, CA). Beginning at 24 hours, patients were instructed to use Neocutis BioCream (Neocutis, San Francisco, CA) to their treated skin. In addition, patients received oral doxycycline 100 mg PO BID for 5 days and valacyclovir 500 mg PO BID for 7 days, as per the routine established prior to this protocol in the investigator's office. The patient's one-week evaluation is shown in *Figure 3C*, the one month follow-up evaluation is shown in *Figure 3D* and his 3-month follow-up evaluation is shown in *Figure 3E*. Treatment settings used for this patient are shown in *Figure 3F*. *Figure 4* demonstrates a 24 year-old Hispanic male with Fitzpatrick Skin Type V with significant acne scars. His evaluation and clinical course is documented in *Figures 4A-F*.

Discussion and Conclusions

All of the patients had significant improvement in their skin and were highly satisfied with their AcuPulse Combo treatment. All of the procedures were well tolerated, and were all able to be carried out under topical anesthesia, without the need

Figures 3A-F: 37 year old male, Skin Type 4 before treatment (A); immediately post treatment (B); one-week post treatment evaluation (C); one month post treatment evaluation (D; three months post treatment evaluation (E); treatment settings (F).

(photos courtesy of Michael H. Gold, MD)

Figures 4A-F: 24 year old male, Skin Type 5 before treatment (A); immediately post treatment (B); one-week post treatment evaluation (C); one month post treatment evaluation (D; three months post treatment evaluation (E); treatment settings (F).

(photos courtesy of Michael H. Gold, MD)

for local anesthesia, tumescent anesthesia, or nerve blocks. Patients reported downtime anywhere from 3-7 days following their laser therapy, all within the expected downtime parameters for ablative fractional resurfacing. No untoward events were noted with these individuals, especially with regard to PIH, again more common in darker skinned individuals. The AcuPulse Fractional CO_2 Laser System Combo treatment modality from Lumenis was safe and reliable in this patient population, making it an ideal fractional one scanner laser therapy option for those truly wanting to individualize the laser treatment to the patient and the condition being evaluated and treated. Its acceptance was high and patient satisfaction was very high.

References:

1. G. H. Sasaki, H. M. Travis, B. Tucker Fractional CO_2 laser resurfacing of photoaged facial and non-facial skin: Histologic and clinical results and side effects. *J Cos Las Ther,* 2009; 11: 190–201.

2. S. B. Cho, S. J. Lee, J. M. Kang, Y. K. Kim, W. S. Chung, S. H. Oh. The Efficacy and Safety of 10,600-nm Carbon Dioxide Fractional Laser for Acne Scars in Asian Patients. *Dermatol Surg* 2009; 35:1–7.

3. J. A. Heinrich. Split-face comparison of fractional ablative CO_2 and fractional nonablative laser devices for skin rejuvenation. Lumenis 2008.

4. R. Saluja, J. Khoury, S. Detwiler, M. Goldman. Histologic and Clinical Response to Varying Density Settings with a Fractionally Scanned Carbon Dioxide Laser. *J Drug Derm*, 2009;8: 1229:32.

5. M. Gold, J. Biron Combined Superficial & Deep Fractional Skin Treatment for Photodamaged Skin – A Prospective Clinical Trial. *J Cos Las Ther*. Submitted for publication.

AMERICA

Lumenis Inc.
Santa Clara, CA, USA
Tel +1 408 764 3000
+1 877 586 3647
Fax +1 408 764 3999
+1 800 505 1133

EUROPE / MIDDLE EAST / AFRICA

Dreieich-Dreieichenhain, Germany
Tel + 49 6103 8335 0
Fax + 49 6103 8335 300

Formello (RM), Italy
Tel + 39 06 90 75 230
Fax + 39 06 90 75 269

London, UK
Tel + 44 20 8324 4200
Fax + 44 20 8324 4222

JAPAN

Lumenis (JAPAN) Co. Ltd.
Tokyo, Japan
Tel + 81 3 5789 8300
Fax + 81 3 5789 8310

ASIA / PACIFIC

Beijing, China
Tel + 86 10 5737 6677

Gurgaon, India
Tel + 91 124 422 33 80
Fax + 91 124 422 33 83

PB-1116140 rev A